



Secondary venous aneurysm following intravenous drug abuse: A case report

Sekundarna venska aneurizma kao posledica intravenozne zloupotrebe narkotika

Miroslav Marković*†, Marko Dragaš*†, Igor Končar*†, Igor Banzić*†,
Siniša Pejkić*†, Nikola Fatić†, Lazar Davidović*†

*Faculty of Medicine, University of Belgrade, Belgrade, Serbia; †Clinic for Vascular and Endovascular Surgery, Clinical Center of Serbia, Belgrade, Serbia

Abstract

Introduction. Venous aneurysm (VA) is a rare condition that can be presented in both superficial and deep venous system. Secondary VAs as well as pseudoaneurysms are usually caused by external spontaneous or iatrogenic trauma. They are often misdiagnosed and inadequately treated. Complications include thrombosis, phlebitis, eventual pulmonary embolism and rupture. **Case report.** We presented a case of secondary VA of the great saphenous vein developed in a young addict following chronic intravenous drug application in the groin region. Aneurysm required urgent surgical treatment due to bleeding complication as it was previously misdiagnosed for hematoma (or abscess) and punctuated by a general surgeon. Complete resection of VA with successful preservation of continuity of the great saphenous vein was performed. Postoperative course was uneventful. Regular venous flow through the great saphenous vein was confirmed on control ultrasound examination. **Conclusion.** VAs are uncommon, among them secondary VA being extremely rare. In cases with a significant diameter or threatening complications surgical treatment is recommended.

Key words:

aneurysm; saphenous vein; diagnosis, differential; histological techniques; injections, intravenous; opioid-related disorders; vascular surgical procedures

Apstrakt

Uvod. Venska aneurizma je retko patološko stanje koje se može pojaviti kako na površnom, tako i na sistemu dubokih vena. Sekundarne venske aneurizme, kao i venske pseudoaneurizme, najčešće se javljaju kao posledica spoljne, neretko jatrogene traume. S obzirom na nisku učestalost, one se često ne prepoznaju i shodno tome nepravilno leče. Moguće komplikacije uključuju trombozu, flebitis, plućni tromboembolizam, pa čak i rupturu. **Prikaz bolesnika.** Prikazali smo sekundarnu vensku aneurizmu lokalizovanu na velikoj veni safeni kod mlade narkomanke, kao posledicu dugotrajnog uzimanja intravenoznih narkotika preko prepone. Aneurizma je zahtevala hitno hirurško lečenje usled akutne hemoragijske komplikacije, zbog toga što je prethodno bila punktirana pod dijagnozom suspektnog hematoma, odnosno apscesa, od strane opšteg hirurga. Učinjena je potpuna resekcija aneurizme, uz očuvanje kontinuiteta safenske vene. Postoperativni tok je protekao bez komplikacija, a uredna protočnost vene safene potvrđena je kontrolnim ultrasonografskim pregledom. **Zaključak.** Venske aneurizme su retke, naročito one sekundarne etiologije. Ukoliko dosegnu značajan prečnik ili prete komplikacijama, potrebno je hirurško lečenje.

Ključne reči:

aneurizma; v.saphena; dijagnoza, diferencijalna; histološke tehnike; injekcije, intravenske; poremećaji izazvani opioidima; hirurgija, vaskularna, procedure.

Introduction

Venous aneurysm (VA) is a rare pathologic condition. The first was described in the popliteal vein by May and Nisnel¹ in 1968. It can be presented in both superficial and deep venous system. Primary superficial VA is considered to be a

consequence of venous reflux distal from a valve². In contrast, primary deep VA is thought to appear due to venous wall weakness, as in Klippel-Trenaunay syndrome³. Both superficial and deep secondary VAs (and pseudoaneurysms) are caused by external spontaneous or iatrogenic trauma⁴⁻⁶. Due to their low incidence VAs are often misdiagnosed and

inadequately treated. In such cases complications can occur and include thrombosis, thrombophlebitis with eventual pulmonary embolism and rupture.

Case report

A 27-years-old female was admitted as emergency due to hemorrhage from a tumefaction in the left groin. The patient had a history of chronic intravenous drug abuse repeatedly using both groins for drug-consuming access. This tumefaction appeared three months earlier and was punctuated as suspected hematoma (or abscess) by a general surgeon in a regional hospital before admission. Because of subsequent massive bleeding a superficial skin suture was applied and followed by compressive bandaging of the groin. The patient was thereafter referred to a vascular specialist.

On admission compressive bandage was removed and a soft, bluish, painful, non-pulsating tumefaction without thrill or bruit about 4×4 cm in diameter was observed. All the arterial pulses in the leg were palpable. As the mass was localized medially from femoral artery pulsation a venous pseudoaneurysm of saphenous or femoral vein was suspected. Due to ultrasound unavailability during emergency hours

the indication for surgery was established on the basis of clinical examination.

Under the regional anesthesia a midgroin incision was made and the region of saphenofemoral junction was accessed. A VA of a terminal part of great saphenous vein was completely exposed as well as unaffected parts of saphenous and femoral vein (Figure 1).

Except the small punctiform lesion on the top of the aneurysm no other defects were noted. There were no signs of suppurative collections or extensive hematomas. Systemic heparin was administered and partial clamp of the saphenofemoral junction applied, followed by complete aneurysm resection (Figure 2). The junction defect was closed with direct lateral suture, in order to preserve superficial venous flow.

The patient recovered well and was discharged on the second hospital day. Control ultrasound presented patent saphenofemoral junction on discharge. No pathological reflux or signs of previous thrombosis were found. However, the patient has never appeared to control examination.

Histological examination revealed VA with signs of wall arterIALIZATION, irregularly intimal and medial fibrosis and thickening (Figure 3). Scattered disruption and lack of elastic and smooth muscle fibers and diffuse accumulation of

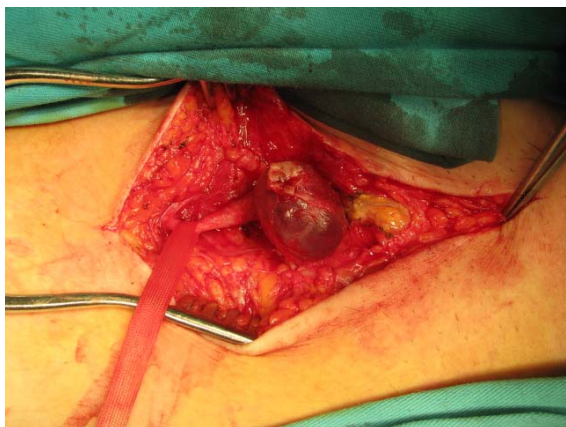


Fig. 1 – Intraoperative finding of venous aneurysm engaging the terminal part of the great saphenous vein.

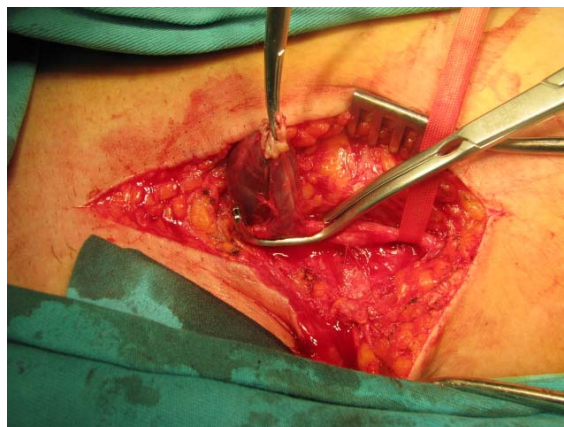


Fig. 2 – Partial clamping of the saphenofemoral junction enabling safe aneurysm resection.

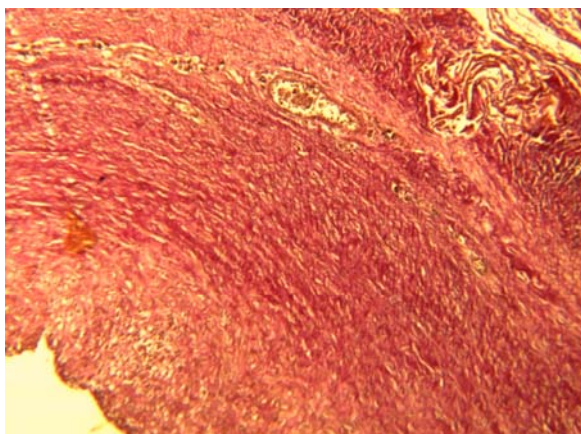


Fig. 3 – Histological finding of resected venous aneurysm shows signs of wall degeneration, irregularly intimal and medial fibron's and thickening (Van Giemsa, $\times 40$).

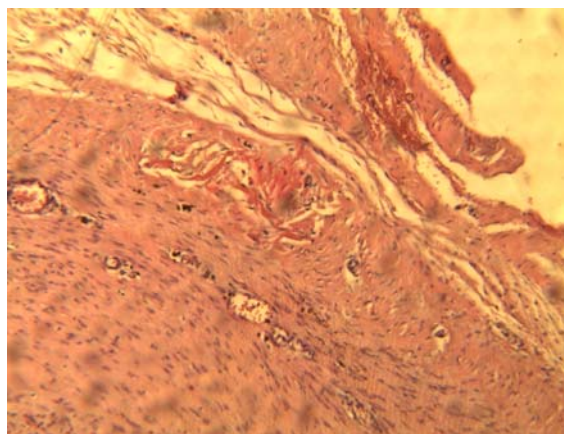


Fig. 4 – Histological finding of resected venous aneurysm shows scattered disruption and lock of elastic and smooth muscle fibers and diffuse accumulation of extracellular matrix (Van Giemsa, $\times 400$).

extracellular matrix was also noted (Figure 4). Nevertheless, all three layers of the venous wall were persisting in the sac, thus suggesting the presence of a true aneurysm.

Discussion

VAs are mostly reported in sporadic cases, many of them pronounced as “the first”, “unique” etc. Indeed, there are only a few series including a significant number of patients being published^{2,7}. However, the definition of VA as a measurement exceeding 1.5 times the adjacent proximal or distal vein in one of these series was quite liberal². Unfortunately there are no universally agreed size criteria to define a venous dilatation as an aneurysm⁸.

Histological findings of VA usually describe a significant decrease in the number and size of smooth muscle cell, decreased elastic fibers and thickening and fibrosis of the intima layer⁹. The terms “endophlebohypertrophy” and “endophleboscclerosis” are used to describe these changes¹⁰. Although posttraumatic in nature, histological evaluation of our patient favored a true VA because all layers of venous wall were present.

There is also a topographic distribution of VAs on central (thoracic), visceral, cervical and peripheral¹¹. Differential diagnosis of superficial VA includes pseudoaneurysms, arteriovenous malformations, enlarged lymph nodes, lipomas and varicose veins⁹. In most cases the correct diagnosis is established after additional investigation, duplex ultrasound being usually sufficient. Our case confirms the diagnostic challenge of VAs as it has been unrecognized previously and punctuated as inguinal hemathoma. It outlines the value of duplex ultrasound in preoperative evaluation however in emergency it is not always available. For that reason medical practitioners should be aware of this rare but potentially serious disease.

The management and indications for operative treatment of this disorder remain unclear. It is obvious that large VAs threatening with complications should be treated surgically; however, there is no consensus about the treatment of small and asymptomatic VA. Some authors recommend observation, compression and surveillance with duplex

scanning, or percutaneous less invasive treatment^{2,12}. Furthermore, there is no strict definition between “small” and “large” VA that would help in establishing indication for surgery. Sessa et al.⁷ estimated the diameter of popliteal VA greater than 20 mm to be clinically significant and should be treated by surgery.

There is a variety of conventional surgical approaches to VA depending on their localization, size, and eventual presence of complications. In VA engaging superficial veins the most simplex procedure is complete removal and ligation, however in our case we preserved a saphenofemoral junction by VA excision and lateral suture due to patient’s young age, in order to keep this main superficial venous outflow tract patent. If VA engages deep venous system, every attempt to restore venous flow should be made including the use of synthetic graft¹³. The role of postoperative anticoagulation is not yet established and is left to surgeon’s preference. In our case we did not administer any postoperative anticoagulation, due to social profile of our patient. However, she never appeared on control exam.

VAs and pseudoaneurysms in the groin following drug addiction are not commonly reported, only one small series of patients being published¹⁴. All of them were treated with complete excision and wound package due to the significant presence of infection. Only one case of iatrogenic true aneurysm of the superficial antecubital vein has been reported and was related to venous cannulation⁸.

Conclusion

Venous aneurysms are uncommon, among them secondary venous aneurysms being extremely rare. In cases with significant diameter or threatening complications surgical treatment is recommended.

Acknowledgements

This work was supported by the Ministry of Education, Science and Technological Development, Republic of Serbia (Grants ON175008 and III41007).

R E F E R E N C E S

1. May R, Nissel R. Aneurysma der Vena poplitea. *Rofo Fortschr Geb Rontgenstr Neuen Bildgeb Verfahr* 1968; 108(3): 402–3. (German)
2. Pascarella L, Al-Tuwaijri M, Bergan JJ, Mekenas LM. Lower extremity superficial venous aneurysms. *Ann Vasc Surg* 2005; 19(1): 69–73.
3. Seery JM, Reyes AM, Rice RD, Dodge AN, Armstrong PJ. Primary venous aneurysms: two case reports. *Am Surg* 2010; 76(2): 224–5.
4. Ward WH, Platx TA, Pond KT, Southern FA, Moore EM. Iatrogenic venous pseudoaneurysm: case report and review of the literature. *Vascular* 2009; 17(6): 355–8.
5. Karaban M, Isbir S, Baltacyoglu F, Caglar MM. False aneurysm of the common femoral vein in a footballer. *Br J Sports Med* 2005; 39(2): e8.
6. Schummer W, Schummer C, Voigt R, Heyne J, Steenbeck J. Pseudoaneurysm - a rare complication of internal jugular vein cannulation: two case reports in livertransplant patients. *Anesthesiol Intensivmed Notfallmed Schmerzther* 2003; 38(8): 542–6. (German)
7. Sessa C, Nicolini P, Perrin M, Farab I, Magne JL, Guidicelli H. Management of symptomatic and asymptomatic popliteal venous aneurysms: a retrospective analysis of 25 patients and review of the literature. *J Vasc Surg* 2000; 32(5): 902–12.
8. Debnath D, Wallace S, Mylona E, Myint F. Aneurysm of antecubital vein: an unusual complication of peripheral intravenous cannulation. *BMC Surgery* 2007; 7(1): 9.
9. Schatz JJ, Fine G. Venous aneurysms. *N Engl J Med* 1962; 266: 1310–2.

10. *Lev M, Saphir O.* Endophlebohertrophy and phlebosclerosis. I. The popliteal vein. *AMA Arch Pathol* 1951; 51(2): 154–78.
11. *Castle JM, Arous EJ.* Femoral vein aneurysm: a case report and review of the literature. *Cardiovasc Surg* 1995; 3(3): 317–9.
12. *Salour M, Dattilo JB, Mingloski PM, Brewer WH.* Femoral vein pseudoaneurysm: uncommon complication of femoral vein puncture. *J Ultrasound Med* 1998; 17(9): 577–9.
13. *Dahl JR, Freed TA, Burke MF.* Popliteal vein aneurysm with recurrent pulmonary thromboemboli. *JAMA* 1976; 236(22): 2531–2.
14. *Johnson JE, Lucas CE, Ledgerwood AM, Jacobs LA.* Infected venous pseudoaneurysm. A complication of drug addiction. *Arch Surg* 1984; 119(9): 1097–8.

Received on June 17, 2014.
Accepted on March 3, 2015.
Online First March, 2016.